ReXErr: Synthesizing Clinically Meaningful Errors in Diagnostic Radiology Reports

HARVARD MEDICAL SCHOOL | BLAVATNIK INSTITUTE BIOMEDICAL INFORMATICS

Vishwanatha M. Rao*; **Serena Zhang***; Julian N. Acosta, PhD; Subathra Adithan, MD; Pranav Rajpurkar, PhD

RAJPURKAR LAB

Motivation

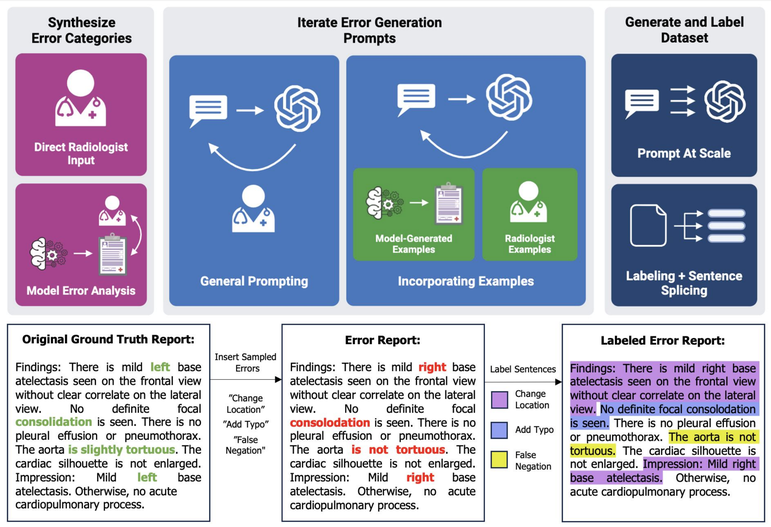

Figure 1: Summary of ReXErr error generation pipeline.

Both human-written and AI-generated radiology reports are liable to errors:

- Human-written reports contain errors due to fatigue, high workload, and subjective interpretation
- AI-generated reports produce errors from algorithmic biases and data limitations

The Chest X-Ray Report Error (ReXErr) method offers a novel solution by:

- Generating synthetic but plausible errors at report and sentence levels
- Creating diverse training data that mimics human and AI-generated errors
- Enabling the development of better error detection and correction algorithms
- Offering a standardized pipeline for synthetic error injection

Error Categories

Error Type	Error Category	Specific Error
AI Generated Report Errors	Content Addition	Add Medical Device
		False Prediction
		False Negation
	Linguistic Quality	Add Repetitions
		Add Contradictions
	Context Dependent	Change Name of Device
		Change Position of Device
		Change Severity
		Change Position
		Change Measurement
Human Errors	Content Addition and Context Dependent	Similar to Above
	Linguistic Quality	Change to Homophone
		Add Typo

Data Synthesis

Error Injection Pipeline

GPT-4o was used to add realistic errors to radiology reports from the MIMIC-CXR train, test, and dev sets [1].

Probabilities are combined using the formula:

$$P(E_c, E_A, E_L \mid T) = P(E_c \mid T) \times P(E_A) \times P(E_L)$$

T refers to the tags present, where $T \in$ {"device", "measurement", "location", "severity"}. The system uses regex to label reports with their respective tags. E_C, E_A, and E_L refer to context-dependent, content addition, and linguistic quality error categories respectively.

A and L represent the number of individual errors present within the content addition and linguistic quality error categories. The individual probabilities are calculated as follows:

Context-dependent

$$P(E_c \mid T = t_i) = \begin{cases} \frac{w'(t_i)}{\sum_{t \in T} w'(t) \times E(t)} & \text{if } T \neq \emptyset \\ \frac{1}{|A|+|L|} & \text{if } T = \emptyset \end{cases}$$

The probability of selecting a particular context-dependent error given a tag depends on the normalized inverse frequency weight assigned to the tag ($w'(t_i)$) as well as the total number of context-dependent errors associated with each tag ($E(t)$).

Content Addition

$$P(E_A) = \frac{1}{|A|}$$

Linguistic Quality

$$P(E_L) = \frac{1}{|L|}$$

Sentence Level Injection

Radiology reports were processed at the sentence level by:

1. Splitting reports into sentences
2. Mapping error sentences to their original ground truth sentences using similarity
3. Using Llama 3.1 to identify error types with two labels:
   a. Label: correct (0), error (1), or neutral (2)
   b. Error class: specific type of error
4. Special cases were handled:
   a. New sentences: original field left blank
   b. Omitted sentences: error field left blank
   c. "Add Opposite Sentence" reclassified as "False Prediction"

This process maintains sentence order and enables direct comparison between original and error sentences.

Results

Report-Level

Ground Truth	Error Report	Errors Injected
Findings: The patient is status post median sternotomy and CABG. The heart size is top normal. The mediastinal and hilar contours are unremarkable. Bilateral calcified pleural plaques are seen diffusely which limits assessment of the underlying pulmonary parenchyma. No focal consolidation, pleural effusion or pneumothorax is clearly demonstrated. There are no acute osseous abnormalities.	**Findings:** The patient is status post median sternotomy and CABG. The heart size is enlarged. The mediastinal and hilar contours are unremarkable. Right calcified pleural plaques are seen diffusely which limits assessment of the underlying pulmonary parenchyma. No focal consolidation, pleural effusion or pneumothorax is clearly demonstrated. There is a suspected left clavicle fracture.	'change location', 'false prediction', 'add contradiction'

Sentence-Level

Original Sentence	Error Sentence	Label	Error Class
Findings: Comparison is made to previous study from ____.	Findings: Comparison is made to previous study from ____.	2	Not Applicable
There is a right-sided PICC line with distal lead tip at the cavoatrial junction.	There is a right-sided PICC line with distal lead tip at the mid SVC.	1	Change Position of Device
There has been removal of the right-sided chest tube.	There has been removal of the right-sided chest tube.	0	Not Applicable
There remains a curvilinear tubular device projecting over the mediastinum.	There remains a curvilinear tubular device projecting over the mediastinum.	0	Not Applicable
This has been seen on multiple images.	This has been seen on muitiple images.	1	Add Typo
There is persistent opacity at the left mid lung field and left-sided pleural effusion which is stable.	There is persistent opacity at the left mid lung field and left-sided pleural effusion which stable.	1	Add Typo
There is no pulmonary edema.	There is no pulmonary edema.	0	Not Applicable
The right lung is relatively clear.	The right lung is relatively clear.	0	Not Applicable
	The patient has had placement of an endotracheal tube.	1	Add Medical Device

Conclusion

ReXErr generated a large dataset of radiology reports with synthetic errors (200,000 train, 4,000 dev, 3,000 test), achieving 83% plausibility rate in a sample clinical evaluation. While the system has limitations - such as inability to generate compound errors or inject errors into AI-generated reports - the dataset provides valuable training material for developing better error detection systems, report correction models, and AI performance enhancement through reinforcement learning.

References [1] A. E. Johnson et al., MIMIC-CXR, a de-identified publicly available database of chest radiographs with free-text reports, *Scientific data* **6**, p. 317 (2019)